

EP CASE REPORT

Percutaneous continuous left stellate ganglion block as an effective bridge to bilateral cardiac sympathetic denervation

Simone Savastano^{1*}, Luigi Pugliese², Enrico Baldi^{1,3}, Veronica Dusi^{1,3}, Guido Tavazzi^{4,5}, and Gaetano Maria De Ferrari⁶

¹Department of Medical Sciences and Infectious Diseases, Division of Cardiology, Fondazione IRCCS Policlinico San Matteo, viale Golgi 19, 27100 Pavia, Italy;

²Department of Surgery, Fondazione IRCCS Policlinico San Matteo, Pavia, Italy; ³Department of Molecular Medicine, Section of Cardiology, University of Pavia, Pavia, Italy; ⁴Department of Intensive Medicine, Intensive Care Unit, Fondazione IRCCS Policlinico San Matteo, Pavia, Italy; ⁵Department of Clinical, Surgical, Diagnostic and Pediatric Sciences, Fondazione Policlinico San Matteo, IRCCS, University of Pavia, Pavia, Italy; and ⁶Department of Medical Sciences and Infectious Diseases, Cardiac Intensive Care Unit, Arrhythmia and Electrophysiology and Experimental Cardiology, Fondazione IRCCS Policlinico San Matteo, Pavia, Italy

* Corresponding author. Tel: +390382501590; fax +390382503161. E-mail address: s.savastano@smatteo.pv.it

A 62-year old male patient with a previous (3 months before) sub-acute anterior myocardial infarction complicated by septal rupture surgically repaired was resuscitated from an out-of-hospital cardiac arrest due to ventricular fibrillation (VF) and then admitted to our Hospital. No acute coronary lesions beyond the known chronic obstruction of the anterior descending artery were found; left ventricular ejection fraction was 40%, electrolytes were normal. Early after admission, an electrical storm (ES) occurred: sustained polymorphic ventricular arrhythmias (pVAs) were elicited by short-coupled polymorphic premature ventricular beats (PVBs). Ventricular arrhythmias were refractory to amiodarone, lidocaine, and magnesium sulfate. After the 8th DC-shock, percutaneous stellate ganglion block (PLSGB) was performed using the anatomical-based anterior approach: 100 mg of lidocaine and 50 mg of bupivacaine were injected. After 7 h free from arrhythmias sustained pVAs recurred despite maximal antiarrhythmic therapy, esmolol, sedation, and intubation. Repeated PLSGBs were the only way to reduce the arrhythmic burden, with a clear worsening of VAs at the end of the anaesthetic's half-life (Figure 1). Therefore, after the 4th transient PLSGB, a spring-wound epidural catheter (Perifix[®] by Braun Germany) was left in place for lidocaine 2% continuous infusion at 7 mL/h. After 7 days with only isolated VAs, continuous PLSGB was stopped and shortly after ES recurred. An urgent attempt of endocardial radiofrequency PVBs catheter ablation was performed but failed because of haemodynamic instability of the patient and polymorphic origin of PVBs. Bilateral cardiac sympathetic denervation (BCSD) was planned but had to be postponed due to septic shock caused by a Klebsiella

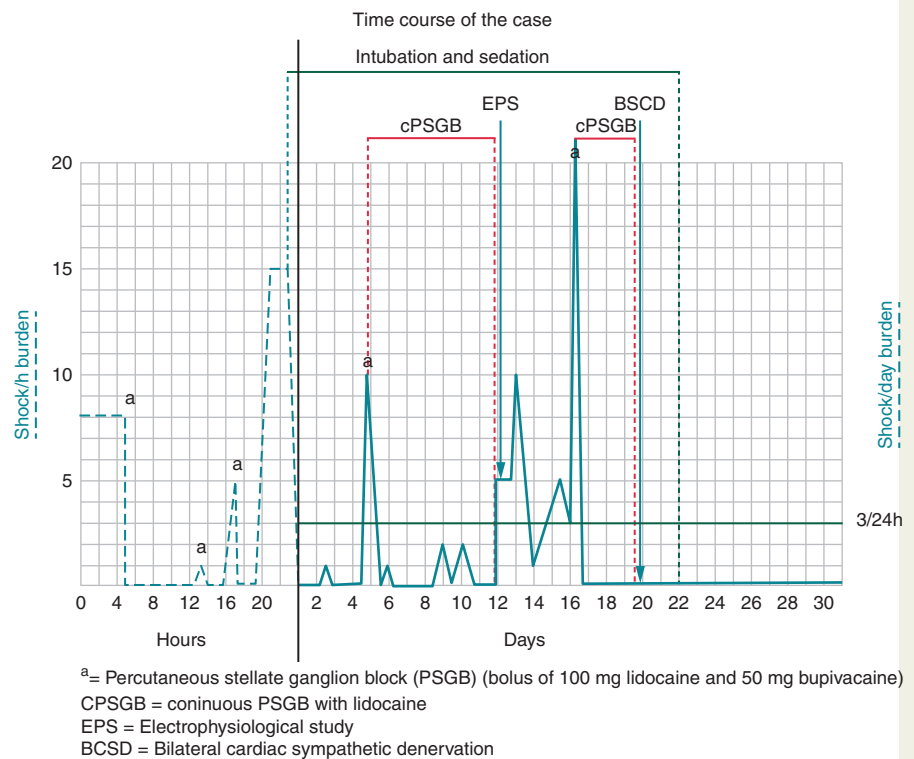


Figure 1 Time course of the case. ^aPercutaneous stellate ganglion block (PLSGB) (bolus of 100 mg lidocaine and 50 mg bupivacaine). BSCD, bilateral cardiac sympathetic denervation; cPSGB, continuous PSGB with lidocaine; EPS, electrophysiological study.

Aerogenes which promoted another severe ES requiring about 20 direct current shocks. As a bridge to BCSD, a second continuous PLSGB was performed; thereafter sustained VAs did not recur. After sepsis resolution, thoracoscopic BCSD was successfully performed and a subcutaneous-implantable cardioverter-defibrillator was implanted. Notably, sustained VF was hardly inducible during implantation. In the subsequent 4 months, no VAs occurred, and left ventricle ejection fraction normalized. Percutaneous stellate ganglion block¹ and BCSD² were described as effective and safe weapons for the treatment and prevention of VAs, respectively. To our knowledge, this is the first reported case of continuous PLSGB performed as a bridge to BCSD. An alternative strategy could have been thoracic epidural anaesthesia³ associated to a more extensive adrenergic block, but also to a not neglectable infective and haemorrhagic risk, in addition to requiring a lateral position and anaesthesiologic expertise. Continuous PLSGB has a lower expected infective potential and can be performed by a trained cardiologist.

Conflict of interest: none declared.

References

1. Meng L, Tseng C, Shivkumar K, Ajjjola O. Efficacy of stellate ganglion blockade in managing electrical storm. *JACC Clin Electrophysiol* 2017;**3**:942–9.
2. Vaseghi M, Gima J, Kanaan C, Ajjjola OA, Marmureanu A, Mahajan A et al. Cardiac sympathetic denervation in patients with refractory ventricular arrhythmias or electrical storm: intermediate and long-term follow-up. *Heart Rhythm* 2014;**11**:360–6.
3. Do D, Bradfield J, Ajjjola OA et al. Thoracic epidural anesthesia can be effective for the short-term management of ventricular tachycardia storm. *J Am Heart Assoc* 2017;**6**:e007080.